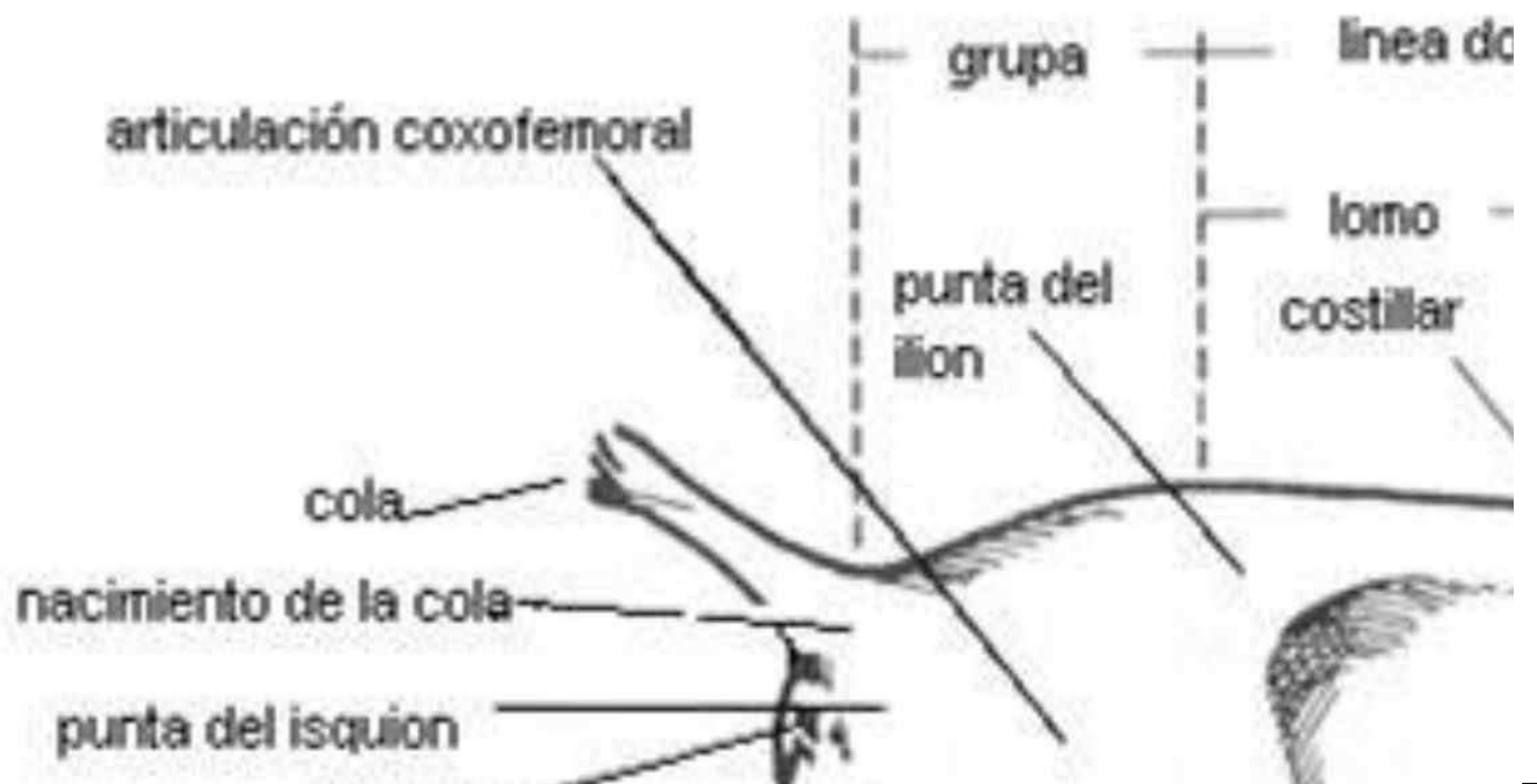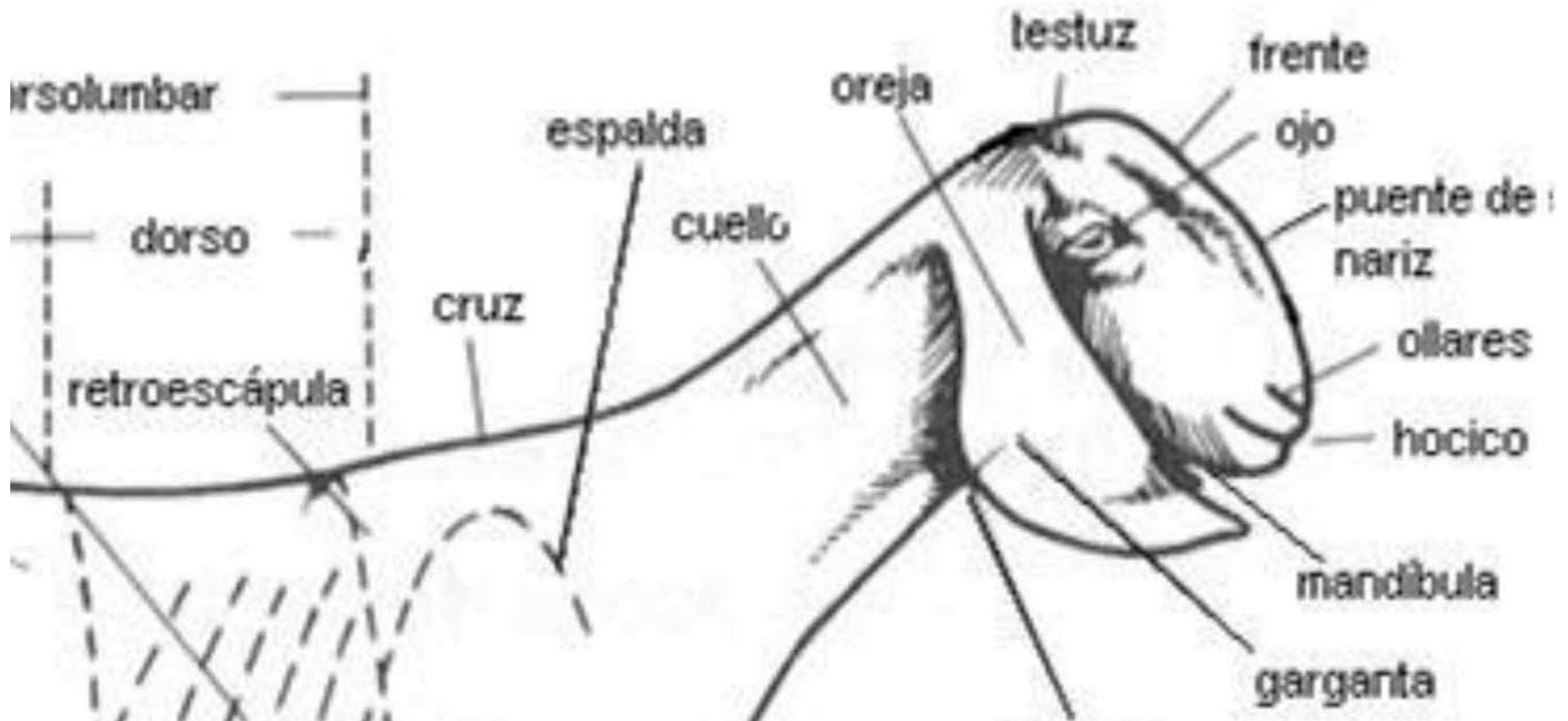
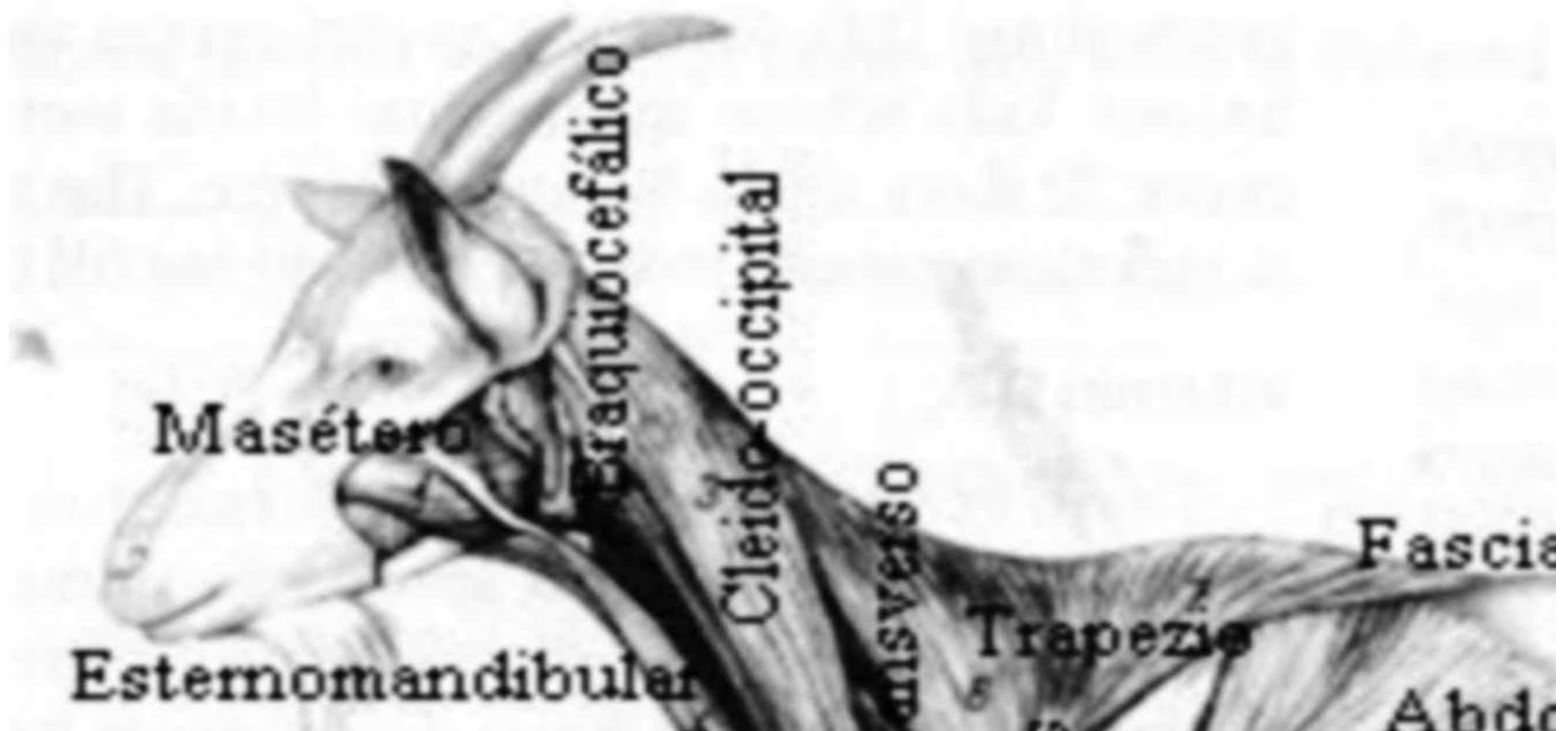


Anatomía Ca



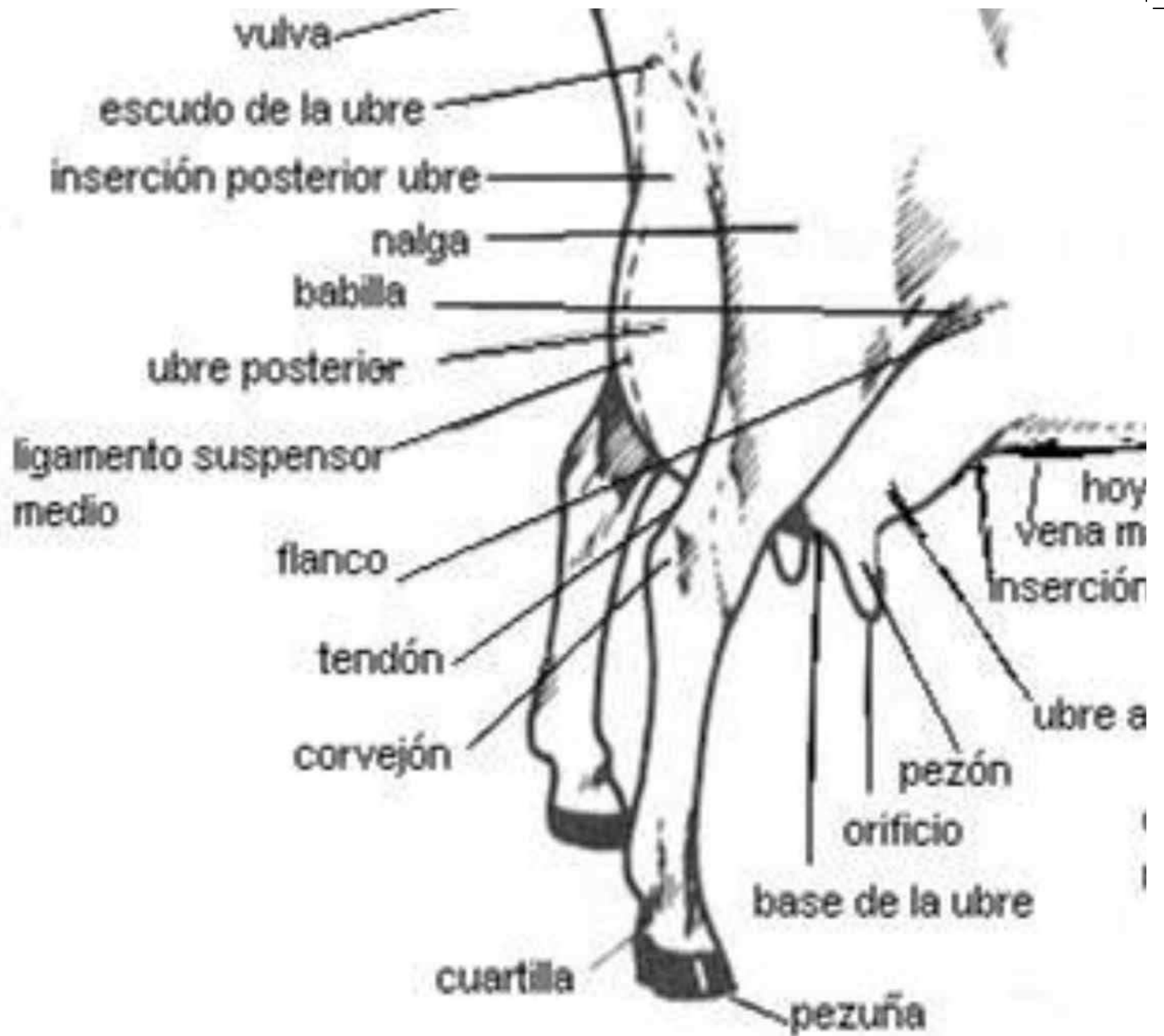
aprina

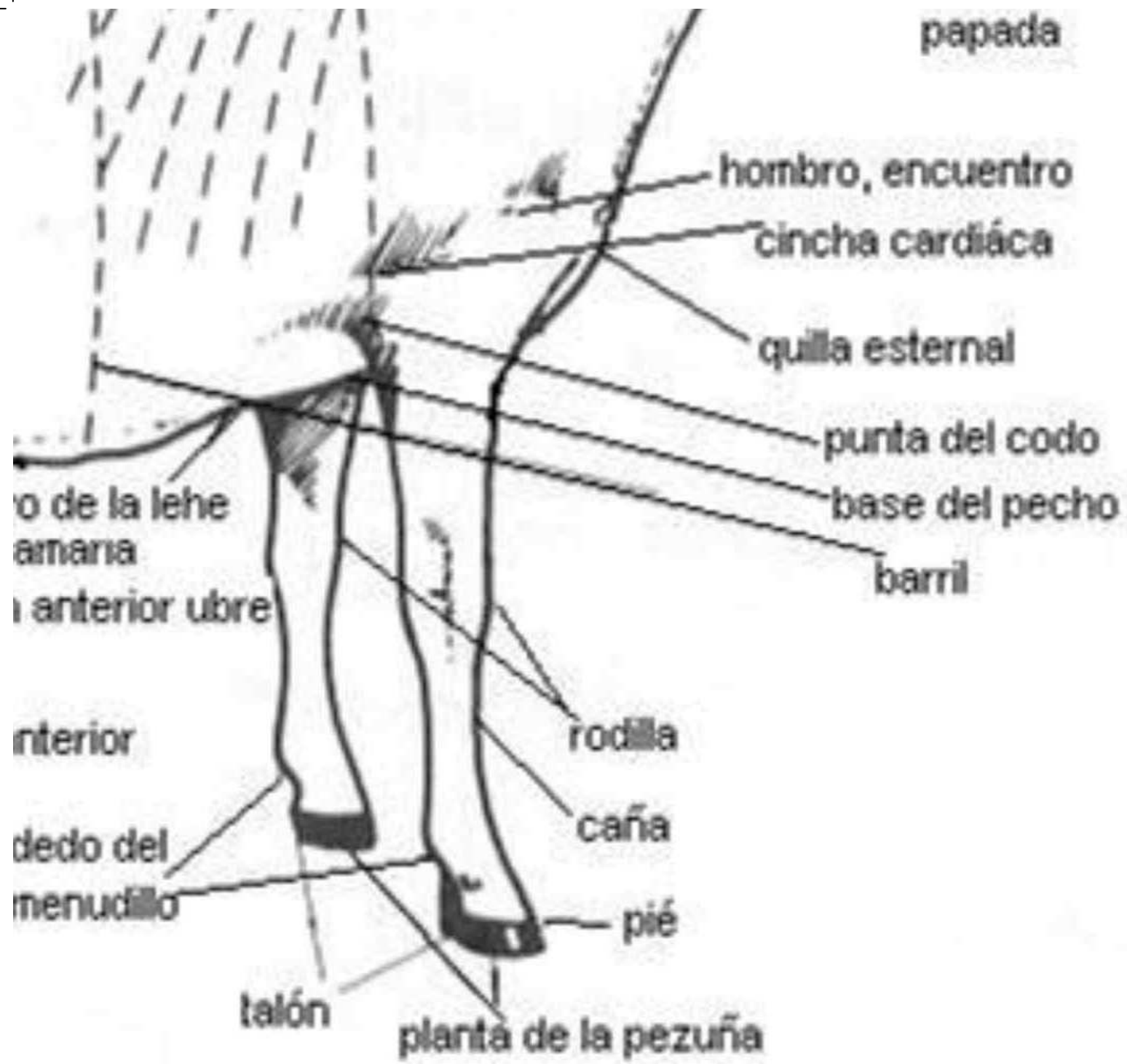


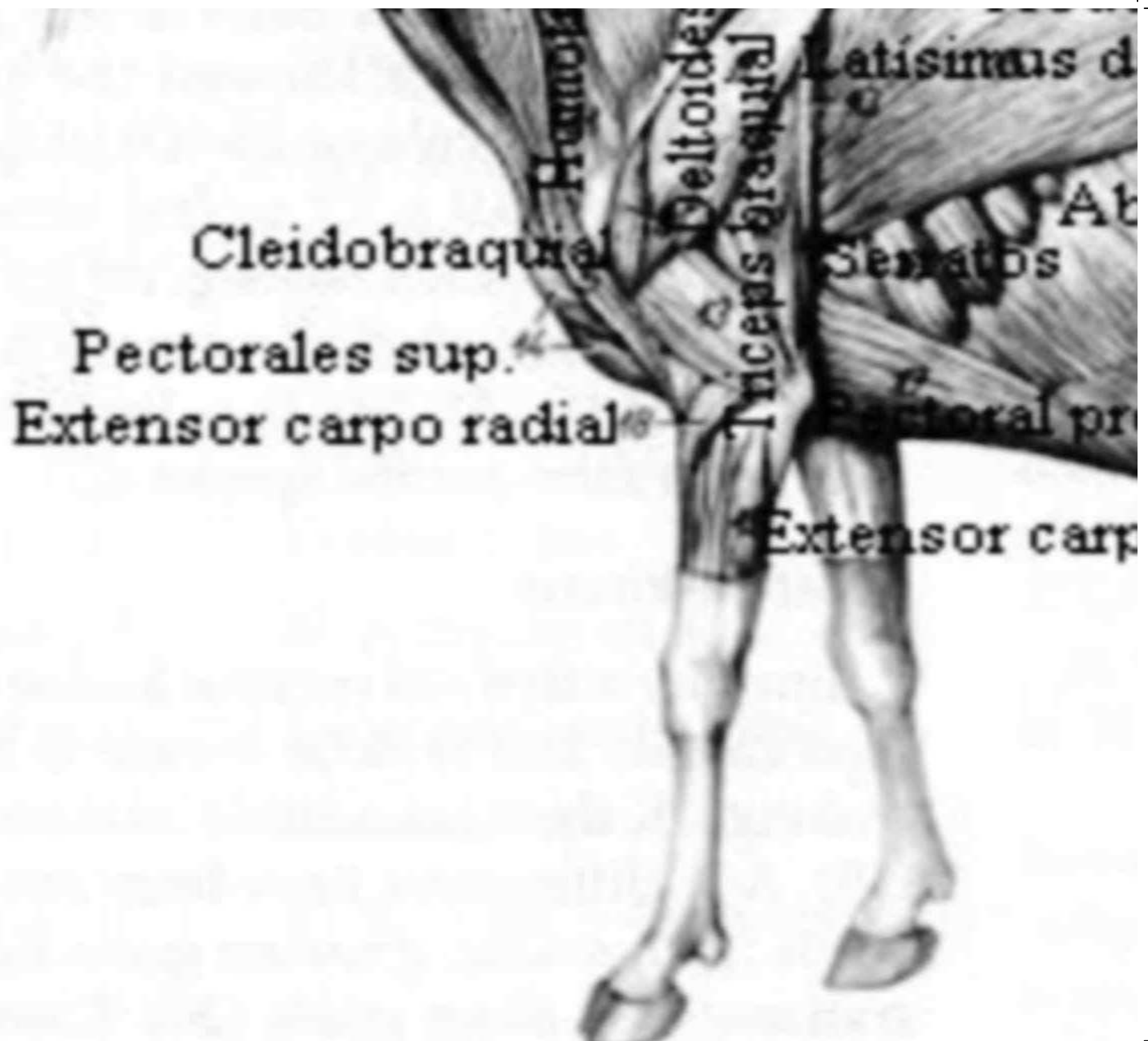
toracico lumbar⁵ Gluteo

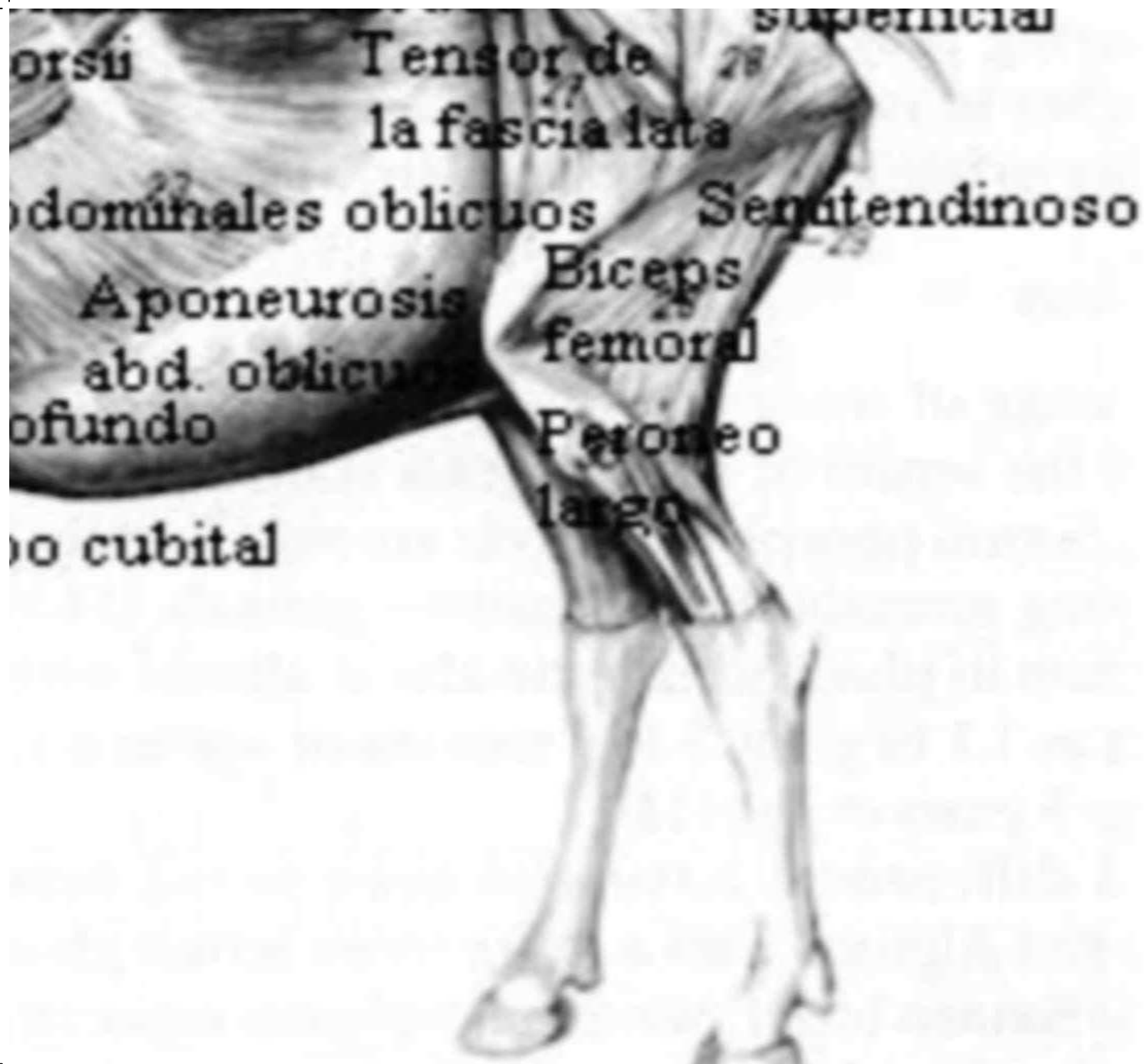²¹ ² medio Gluteo

ominales ablicuda superficial









orsu

Tensor de
la fascia lata

superficial

dominales oblicuos

Semitendinoso

Aponeurosis

Biceps

abd. oblicuo

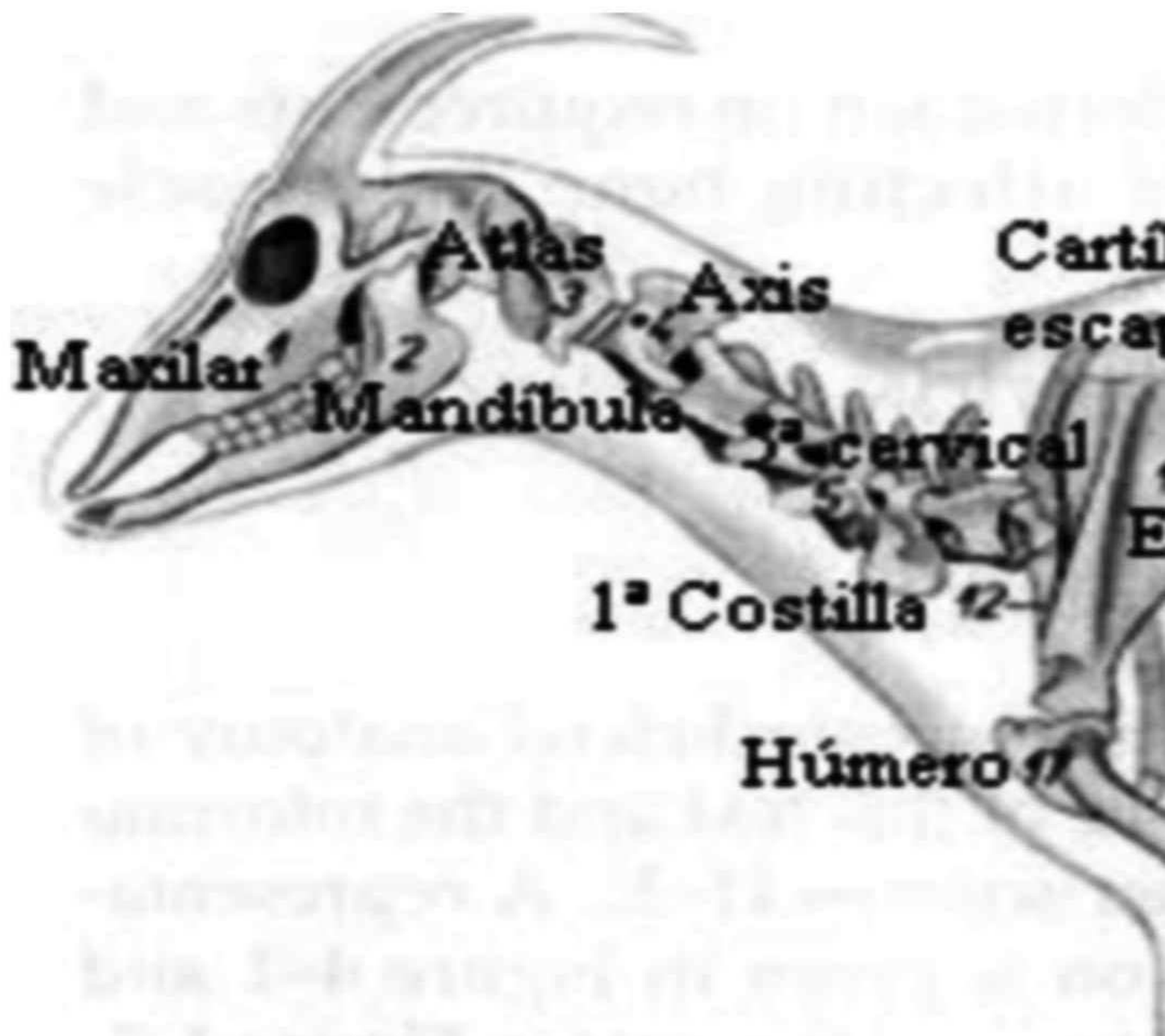
femoral

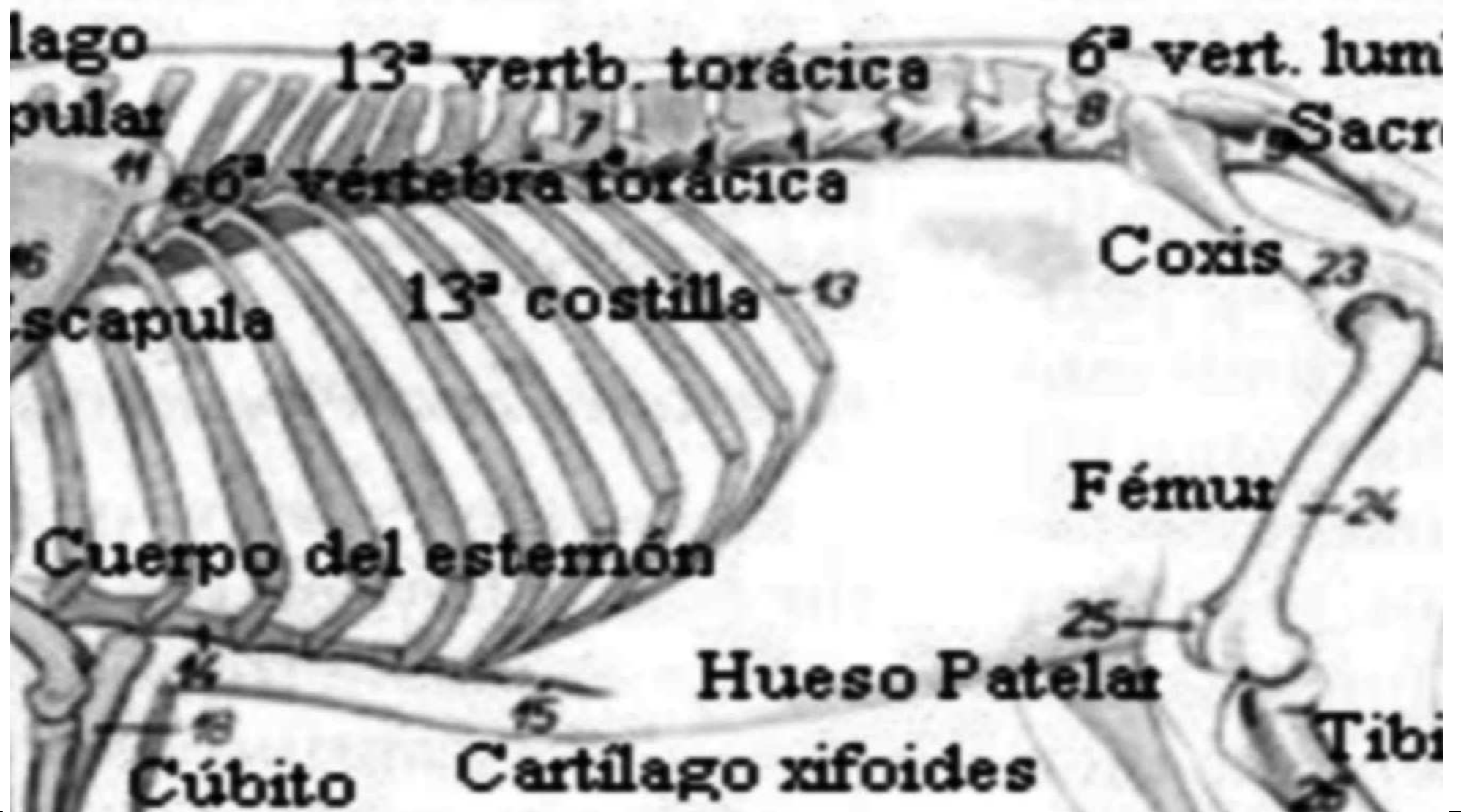profundo

Peroneo

o cubital

largo



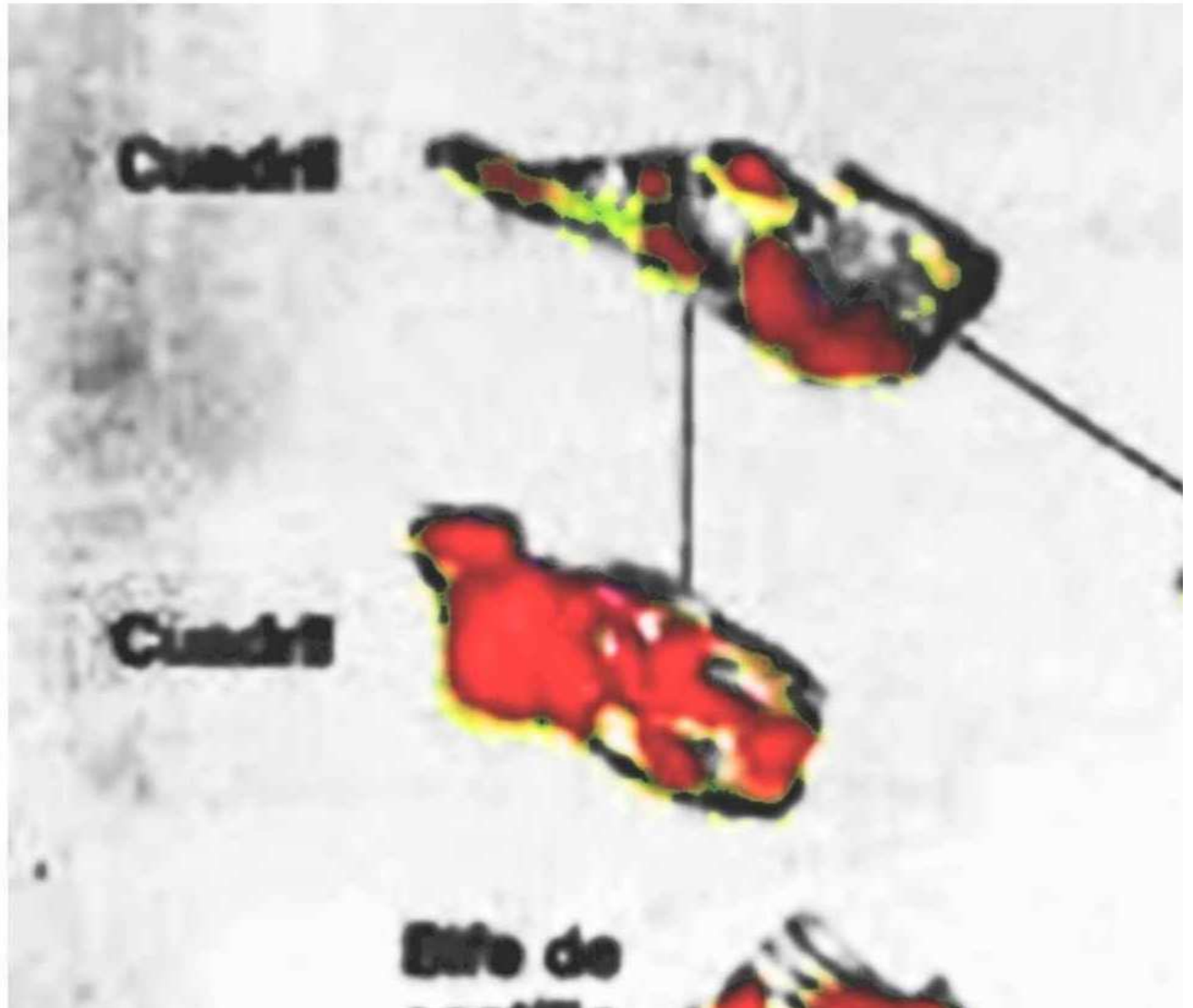


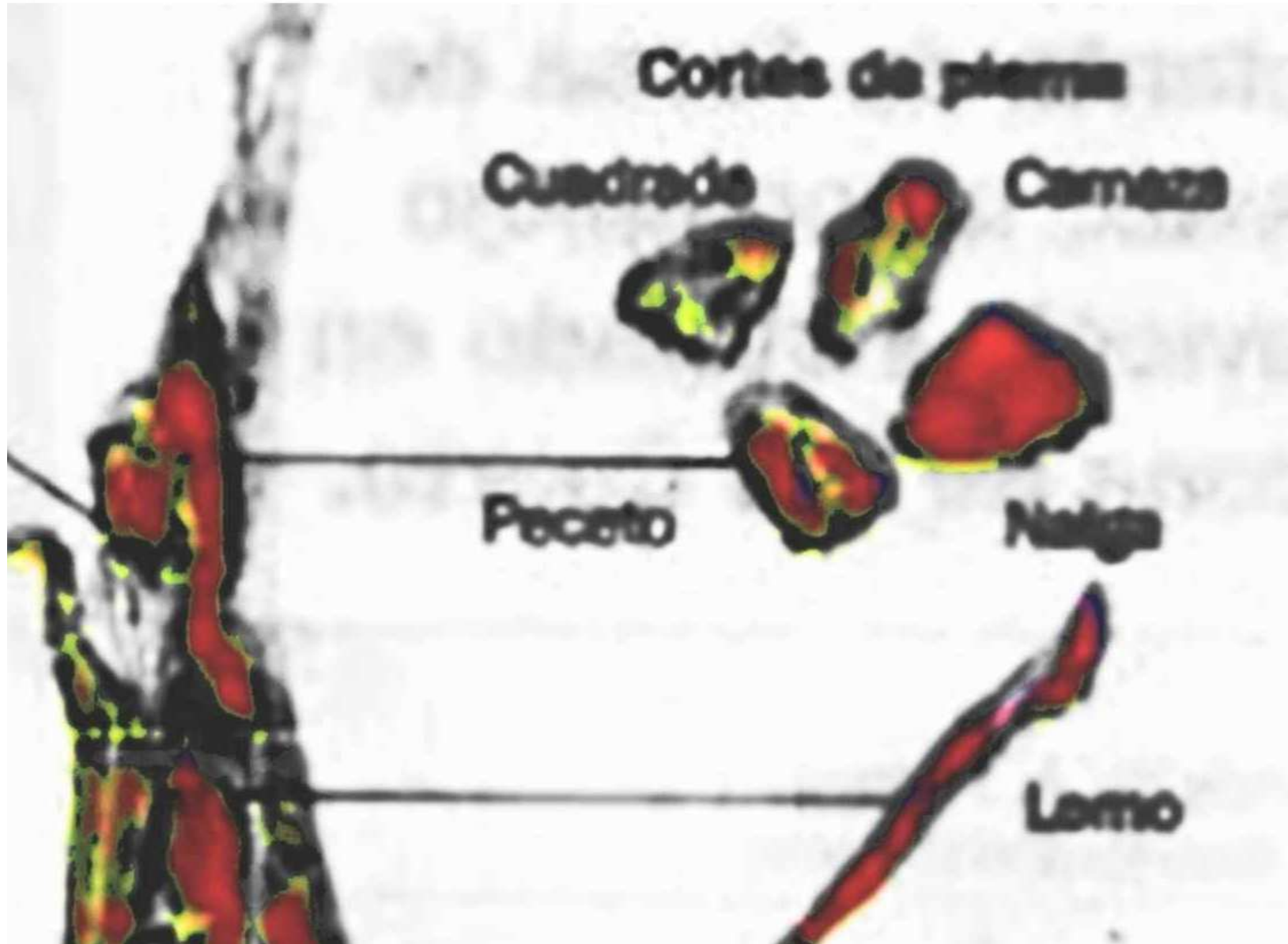
bar

o Vert.

coxigeas

la





Radio 19-

Huesos carpianos 20-

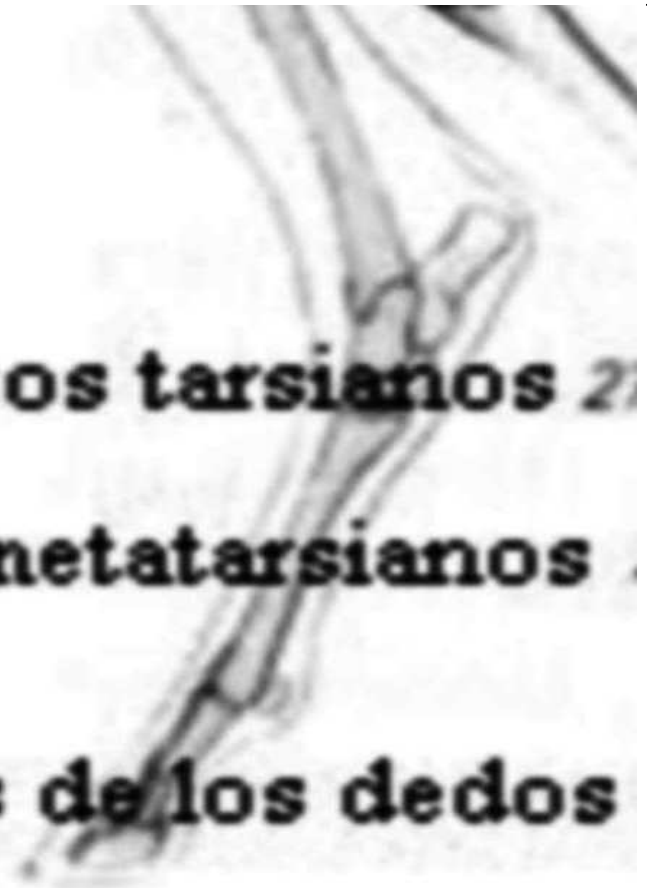3-

Huesos de los d



3° y 4° metacarpiano

dedos



Huesos tarsianos 2°

3° y 4° metatarsianos

Huesos de los dedos

